

Animal Clinic of Granger

www.grangervet.com

This case study is presented to inform pet owners of an interesting medical case and to display the dedication and determination of this family for their pet.

Signalment: Midnight Dwyer, a 2 month old female domestic shorthair kitten recently adopted from a local shelter.

Midnight presented to our office in mid-February 2009 as a tiny kitten of 2.3# for a fever of 107°F (normal is no more than 102.5°F), severe weakness, vomiting, dehydration, an eye infection and a severe respiratory infection involving the lungs. Antibiotic injections were prescribed along with fluid therapy as Midnight was not eating and started with intermittent vomiting. Her family knew that the prognosis for a recovery was very poor, but wanted to give their newly adopted a pet a fighting chance.



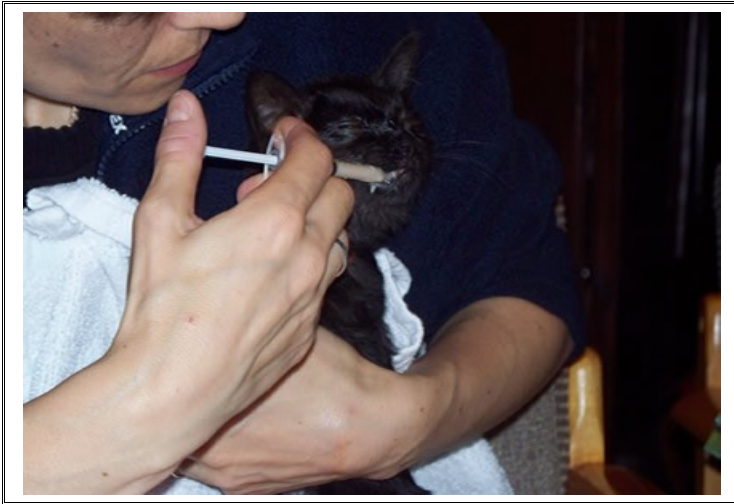The following morning, Midnight's temperature was much improved at 102.2°F and she maintained her weight. She was hospitalized in the Isolation ward of the hospital to prevent exposure to other pets during this time of her severe illness. Our support staff goes to great lengths to follow certain procedures and protocols for infectious diseases in our isolation ward patients to prevent the spread to other hospitalized pets and to protect the ill pets in for treatments. Additional injectable fluids, vitamins, electrolyte replacements, antihistamines and antibiotic therapies continued for Midnight. Eye medications and oral antibiotics with oral calorie supplements were implemented as the vomiting stopped.

There was great difficulty all along with trying to feed Midnight because she was severely congested and could not smell her food. When cats are unable to smell their food, most will not eat. The treatments continued with additional medications to aid in reducing the severe congestion and finally, the next day, Midnight began eating small amounts of dry kitten food on her own.

Animal Clinic of Granger

www.grangervet.com

Seven days following the initial exam, Midnight was alive and making progress. She was still very thin and underweight, but at least was now able to eat and drink without vomiting. We were able to slowly wean her from the injectable therapies and follow-up with oral medications instead. In addition to the antibiotics and other medications to help her breathing and her eye infection, oral anti-virals were initiated and Midnight continued over the next few weeks to improve.



One month after our first meeting, Midnight's eyes became severely infected to the point that her corneas (outer clear layer of the eye) were filled with blood vessels, cloudy and ulcerated from infection making it very difficult for her to see. Although she was making huge leaps and bounds with her weight, appetite and the healing process, this eye infection was a huge set-back in her overall recovery. The initial severe upper respiratory infection was still lingering and was the cause for this problem with her eyes. Another round of oral medications was initiated as well as eye medications to be administered at home six times a day. Several weeks of intensive treatments and frequent rechecks led to resolution of the eye infection and complete return of vision without long-term side-effects.


It was now 8 weeks from the day in February when Midnight first entered our practice and she was doing better than ever. She had more than doubled her weight and it was time for her spay surgery. She was very active and would jump from the floor to the window ledge in the exam room to watch the birds outside. The main concern at that time was if the stress of surgery would cause another flare-up of the upper respiratory infection. We continued eye medications, oral anti-viral and antibiotic therapies. Midnight's pre-anesthetic bloodwork panel which checks major organ function such as kidneys, liver, pancreas as well as red cells, white cells and platelets all checked out as normal without any abnormalities present. Her anesthetic protocol included sevoflurane inhalant anesthesia which is a safer anesthetic than most used in a vast majority of human surgical procedures, so the big day was here

Animal Clinic of Granger

www.grangervet.com

and we proceeded with surgery. Midnight did great for surgery and handled recovery well. She took her pain medications in hospital and at home without any trouble and made a complete and uneventful recovery.

Occasionally, Midnight would have a relapse of sneezing without any further upper respiratory signs, so we were gradually able to wean her from the oral antibiotics and eye medications. She remained very active, with a good appetite and continued to gain weight and grow. The oral anti-virals continued for several more weeks into the month of June and she was weighing in at a normal 6.1#.



I can happily report today that Midnight is a happy, healthy, frisky indoor cat pampered at home like the princess she is and also loved very much by everyone here at the Animal Clinic of Granger. We as well as Midnight for sure are blessed to know and work with the Dwyer family. Thank you for giving this wonderful girl a second chance at life!!

Dr. Jennifer Perusek
Animal Clinic of Granger
14955 S.R. 23
Granger, IN 46530
574-277-0221